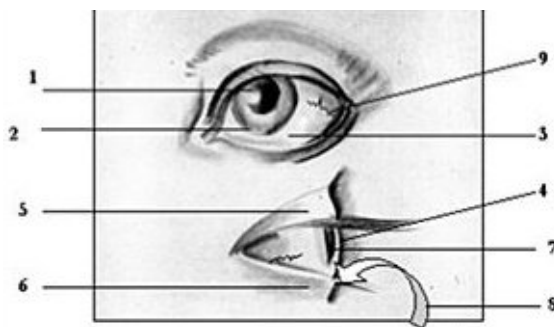


## Color Changes in Scleral Capillaries and Their Clinical Significance: Diagnosis and Treatment Protocol

By Holmes Keikobad, MBBS, DPH (Ret.), Dipl. Ac., LAc

The 61st difficult issue in the *Nan-Ching* places great emphasis on the diagnostic value of color changes in the face.<sup>1</sup> This article discusses the often-seen (and frequently missed) color changes in the scleral capillaries, which form an integral part of the canvas of the face, and deliver a wealth of information to the astute diagnostician.

A common underlying pathology is Fire oppressing Metal, which is the pathology under discussion in this article. The diagram below, as a preamble, lists the elemental qualities of the parts of the eye involved, and the natural colors they are related to.

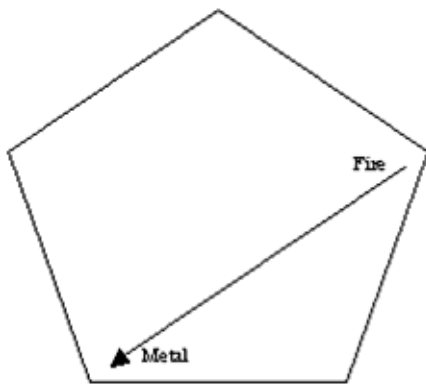


Five-Element quantities of the visible parts of the eye. Image © 2002, Dr. Holmes Keikobad and its licensors. All rights reserved.

1. **Pupil** - Water element, dark black, deep, recessed, unsubstantial
2. **Iris** - Wood element, active, moving, changes like the wind, often green or blue
3. **Sclera** - Metal element, white, malleable, gives structure to eye, opaque
4. **Cornea** - Metal element, continuation of sclera, when invaded shows white

5. **Upper eyelid** - Liver, because of GB 14 superiorly and GB 1 at outer canthus
6. **Lower eyelid** - Stomach, because of the ST line from ST 1 to ST 4 inferiorly
7. **Aqueous humor** - Water element, watery, holds no shape
8. **Conjunctiva covering insides of eyelids** - Fire element, laced with capillaries
9. **Scleral capillaries** - Fire element, blood vessels, carry blood, colored red

### Five-Element Configuration of Illness



Natural bi-elemental progression of scleral invasion. The invasion of the white sclera by the red of the capillaries is one of the most graphic validations of the Five-Elemental iconography in its oppressive *ko* cycle character.

The figure below follows the natural progression of the illness, which, if followed step-by-step, leads to an inescapable diagnosis and a made-to-order treatment protocol. Of particular note is the final and pernicious extension, by the same dynamics, of the process into the cornea, resulting in blinding opacities, a serious condition with unpleasant prognosis and meriting immediate attention.

Please read sequentially from one to nine.

1. The Fire yin is consumed by an overwhelming or ongoing episode of sadness, fear, or both.
2. This causes internal Fire element imbalance, which results in an exuberant Fire yang, which is basically a Small Intestine excess.
3. The excess in Fire in time oppresses Metal by the *ko* cycle connection, and erodes the integrity of the element.
4. A weak Fire element in imbalance is unable to nourish the son Earth, which in turn cannot support its son Metal. All this sets the stage for a serious and concerted invasion of Fire into the white scleral matrix of Metal.

5. The Metal element in time disassociates in its unity, and causes its yin Lung to depress and yang particle Large Intestine to register an excess.
6. This induces a dryness of the fluid on the sclera, and a raised tendency to heat.
7. In this matrix, Heart Fire invades with a proliferation of capillaries that contain the essence of Fire, its blood.
8. The central focus of sclera is the cornea, and the capillaries tend toward this.
9. In time and without treatment, the cornea is invaded and becomes opaque, which is cloudy and white. The scleral invasion of the capillaries is complete.

### **Symptoms Accompanying the Scleral Invasion**

The presence of scleral capillaries signifies a situation in which Fire has oppressed Metal by the *ko* cycle relationship and has entered its substance. Initial symptoms will be those of a depressed Heart yin and a resultant rising Fire yang, and may present as palpitations, arrhythmia, hypertension, insomnia, and the typical neck and shoulder pain along the track of the Small Intestine channel at the medial border of the scapulae.<sup>2</sup> Later, the *ko* invasion shifts the arena of pathology to Metal, where a yin deficiency surfaces coupled with a yang excess in Large Intestine presenting as colitis, polyps, hemorrhoids that occasionally bleed, and chronic constipation. The skin is overly dry and may present a trademark lack of sensible perspiration, a tendency to precancerous growth, and if untreated, frank lesions of squamous cell carcinoma or worse.

The tongue renders useful and dependable changes:

- In terms of afflicted Heart *qi* there is a linear midline fissure, along the whole length of the tongue, or on part thereof. Another sign is that the tip is often bilobular, with each portion protruding well beyond the median apex.
- In terms of Lung, there is a typical narrowing of the anterior third, which signifies constrained Lung *qi*, or a restrained chest, which houses the lungs. Another common sign is the presence of two fissures, or two small linear depressions, laid anteroposteriorly on each side of the midline, in the anterior four-fifths of the tongue, just short of the tip.

### **Deducing Color Changes in Capillaries on Sclera**

The interplay of colors is between a white matrix and a red overlay, the white changing by the color admixed in it, and the red according to its dynamic status, which may vary from free-flowing to stagnated, and from anemic to nearly clotted:

- If the capillaries are few and clearly red, the invasion is recent and the illness, a Heart yang excess, is in an acute phase.
- If the capillaries are more numerous and somewhat of darker hue, the condition has become chronic and the illness, entrenched.
- If the capillaries have a clear dark purple discoloration, the illness involves an element of Heart and blood stagnation.
- If capillaries show a breakage and extravasations of blood onto the sclera, apart from the root pathology, the Spleen is also deficient and cannot keep the blood within the vessels.
- If the extravasated blood shows a yellowish tinge, a Spleen deficiency is confirmed.
- If the extravasated blood is reddish or pinkish, the breakage is recent.
- If the extravasated blood is purplish or darkish, the breakage is of a longer duration.
- If the extravasated blood is frankly black, the disturbed Fire-Water axis is tipping towards Water, which is to say, a consumed Heart *qi*.
- If the capillaries show a kinking or narrowing in some sectors, again the SP is in disarray and has allowed the vessel walls to cave in.
- If the capillaries are thick at the origin, the illness is of long duration and may prove difficult, though not impossible, to treat.
- If the capillaries are tortuous, the illness has run a long course, where the invasion has encountered, at times, a valiant resistance from Metal.
- If the capillaries have invaded the cornea, the illness is well advanced and needs immediate attention.
- If capillaries criss-cross and have many branches, there may be an almost unrestrained emotional vacillation between sadness and grief.
- If the capillaries are blurred or flaked, the clearly marked elemental integrity between Fire and Metal is disintegrating.
- If there is a brownish spot on or removed from the capillaries, the Metal is dry to the point of pathological heat.

## The Logical Treatment Protocol?

Because this is a *bi*-elemental illness, with deficiency on Fire element and an excess on Large Intestine, one tones the Heart with a mother Wood point, and reduces the Metal with a son Water point. An efficient way to do that is to use 5-*shu* specialized points on whichever channel is "open" at the time on the 24-hour horary clock. 3 The table below gives the points that can be applied during the usual clinic hours. A more detailed study of the whole 5-*shu* grid spread on the horary clock gives more choice of points and latitude of application:

### Table Listing Time-Specific Wood-Mother and Water-Son Points

These are element-specific, time-sequenced 5-*shu* points which tone a deficient Heart yin and reduce an excess Metal yang at any particular time during the day. They should be used exclusively within their specific time frames. Other auxiliary points may become necessary to contain emergent symptoms.

### Table Listing Scleral Capillary Changes as a Useful Checklist

TABLE: CHECK NEAREST MATCH FOR THE CAPILLARY PROFILE AND READ FINDING	
CHECK APPROPRIATE BOX	READ MATCHING FINDING
<input type="checkbox"/> Capillaries are red	The HT Yang is in a state of acute Excess.
<input type="checkbox"/> Capillaries are of a darker hue	The HT Yang Excess has turned chronic.
<input type="checkbox"/> Capillaries are darkish purple	HT BL and SP are in a state of stagnation.
<input type="checkbox"/> Capillaries are bleeding into sclera	Apart from the root pathology, the SP is Deficient.
<input type="checkbox"/> Enlarged BL is yellowish	A SP Deficiency is confirmed.
<input type="checkbox"/> Enlarged BL is purplish	A SP Deficiency is coupled with a BL Stagnation.
<input type="checkbox"/> Enlarged BL is purplish	A SP Deficiency is coupled with a BL Stagnation.
<input type="checkbox"/> Enlarged BL is fleckily black	A HT Qi Overused is leaning to Water element.
<input type="checkbox"/> Capillaries are thickened and narrowed	A SP Deficiency is indicated.
<input type="checkbox"/> Capillaries are tortuous	The illness has had a long course and is chronic.
<input type="checkbox"/> Capillaries have invaded corners	A HT into Metal invasion is confirmed.
<input type="checkbox"/> Capillaries are blurred	Fire-Metal integrity is giving way.
<input type="checkbox"/>	
<input type="checkbox"/>	
<input type="checkbox"/>	

Scleral capillary invasion is a fairly common sight in the clinic. Here are the possible changes you may come across, listed in a handy tabulated fashion. All you do is match the ones that apply, check the column alongside and integrate the inferences in your diagnosis. The list is open-ended, and you can add to it as you come across other capillary configurations and hues.

## Conclusion

Rarely does one see the supporting and restraining connections of the Five-Element grid so apparently displayed. Even less frequently does one see these so clearly pre-empting a diagnosis, and a treatment protocol.

Scleral capillaries, though vitiated in their role, readily suggest their own remedy, and become, as a final gesture, when the treatment is correct, the vivid monitors of a favorable prognosis by becoming entirely regressed and invisible.

### *References*

1. Unschuld PU, ed. *Nan-Ching. The Classic of Difficult Issues*. Part II, chapter four, "On Illness," the 61st difficult issue. Regents of the University of California: University of California Press, 1986, p. 539.
  2. Matsumoto K, Euler D (eds.) *Kiiko Matsumoto's Clinical Strategies*. Published by Kiiko Matsumoto International, 2002. Chapter: "Blood Pressure and Cardiac Problems," pp. 120 to p. 131. This work introduces a masterful understanding of body symmetry, and how it can cause problems of raised or lowered blood pressure. Scleral capillaries are a heart-based illness in the least. Matsumoto takes you to the consideration that it can also be a manifestation of asymmetry or stagnation of blood and *qi*.
  3. Keikobad H. *Point Locator Chart for Time-Specific High Energy 5-Shu Toning & Reducing Points*. TruSelf Inc.: Scottsdale, AZ. 2002. Order at (888) 878-7353.
- 

Click [here](#) for more information about Holmes Keikobad, MBBS, DPH (Ret.), Dipl. Ac., LAc.



Page printed from:

[http://www.acupuncturetoday.com/archives2004/nov/11keikobad.html?no\\_b=true](http://www.acupuncturetoday.com/archives2004/nov/11keikobad.html?no_b=true)