

[IMAGE]

*Acupuncture Today*

October, 2001, Vol. 02, Issue 10

## **Direct Electric Acupuncture for Patella Chondromalacia: A Preliminary Report of a Clinical Study**

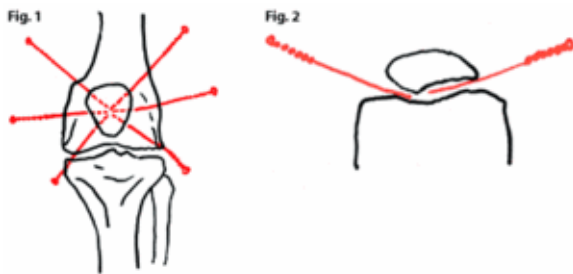
By Hua Gu

Chondromalacia of the patella is common among athletes and people over 40. It is caused by direct trauma or chronic injury to the knee joint. Although it is often referred to and treated as a discernible ailment, *chondromalacia patellae* is best thought of as a symptom.

The patella contains the thickest layer of cartilage in the body. It has five facets or ridges: superior; inferior; lateral; medial; and odd. The "odd" facet is most frequently the first part of the patella to be affected in *chondromalacia patellae*. *Chondromalacia patellae* is the softening and subsequent roughening of the patella's hyaline cartilage. This malady presents itself as grinding beneath the patella and may cause related swelling and pain. A definitive diagnosis is made through visual inspection during arthroscopy.

*Chondromalacia patellae* is most often, if not always, the result of biomechanical changes affecting the lower extremity. As such, it may be treated symptomatically by acupuncture.

### **Acupuncture Techniques**



**Figure 1 and 2:** Insertion of acupuncture needles for the treatment of chondromalacia patellae. After sterilizing the skin of the patella area, the acupuncturist pushes the medial side of the patella outward to open the space between the patella and the anterior surface of the medial femoral condyle. The acupuncturist inserts a needle (32 gauge, 2") to *xi yan* (extra). The needle should be right between the patella and femoral cartilage and should reach the medial side of the lateral condyle. The patient will have the *de qi* sensation. Two more needles should be inserted about half an inch

away from **xi yan**, each along the medial edge of the patella. Visualize the patella as a clock. *Xi yan* is at 7 o'clock. Insert the first needle there, then insert needles at 9 o'clock and 11 o'clock. The insertion is oblique, toward the center of the patella.

On the lateral side of the knee, push the patella toward the midline of the body. Insert needles at ST 35, then at two points corresponding to 3 o'clock and 1 o'clock. The needles should be placed in the patellafemoral joint. Then connect the electric stimulator to all of the needles (negative on the medial side, positive on the lateral side) with a 5Hz intermittent wave. The stimulating time is 20 minutes. A course of treatment is three times a week for three weeks.

## **Results**

The results are based on clinical findings, x-ray and MRI tests.

Excellent: No pain; no signs and symptoms; no discomfort when squatting or kneeling down; no pain when walking up or downstairs. Followup for six months without recurrence.

Good: Pain, symptoms and signs significantly decreased; mild discomfort when squatting or kneeling down. Followup six months with mild discomfort.

Fair: Pain, symptoms and signs decreased; some difficulty when squatting or kneeling down. Followup six months with slight to moderate discomfort.

Poor: No effect or worse.

Thirty-two cases were treated between 9-30 times by the same acupuncturist. Among the 32 cases, 10 were judged as "excellent" (31.1%); 12 "good" (38%); 3 "fair" (9.4%) and 7 "poor" (22%).

## **Discussion**

Direct electric acupuncture is the key for this group of patients. The cartilage in *chondromalacia patellae* is damaged by many different causes. Physical examinations such as Clark's sign, the McConnell test, the passive patellar test and Zohler's sign can help make the diagnosis. X-rays with skyline or sunrise view and knee joint MRI show clear images of the cartilage shape and damage. From the TCM point of view, the diagnosis is the same as bi syndrome, no matter what the cause. After a series of electric acupuncture treatments, most patient knee joint swelling and pain subsided, and range of motion improved.

Electric acupuncture may have the following effects on treatment for chondromalacia of the patella:

1. Direct stimulation by electric current in conjunction with the needles applied to the impaired area may help the regeneration of cartilage.
2. Acupuncture needles inside the joint capsule may relieve synovitis, which will decrease the secretions of the synovial membrane and reduce pain.
3. Most cases in the poor group had moderate to severe misalignment, such as genu varus or valgus, or abnormal Q-angle. These conditions can induce unequal pressure and stress distribution in the femoropatellar joint and cause necrosis of cartilage and cyst formation under the cartilage. Electric acupuncture is a good method to relieve the symptoms of chondromalacia.
4. Perhaps it is the electric current directly working on the joint surface, or the needles' direct contact with the cartilage, that reduces the pressure inside the joint and relieves the symptoms.
5. Another possibility is that electric stimulation changes the viscosity and pH of the joint's synovial fluid to alter the irritation to the synovial membrane.

Further study is necessary to assess what happens inside the joint. Arthroscopic exploration is needed to confirm the changes pre- and post-electric acupuncture treatment.

#### *References*

1. Gu H. *Clinical Traditional Chinese Medicine, Orthopedic Volume*. Chinese Medical Science Publisher, 1st ed., 1989.
2. Fulherson JP. Evaluation of the peripatellar soft tissues and retinaculum in patients with patellofemoral pain. *Clin Sports Med* 1989;8:197.
3. Goodfellow J, Hungerford DS. Patellofemoral joint mechanics and pathology: chondromalacia patellae. *J Bone Joint Surg* 1976;58B:291.
4. Pickett JC. *Chondromalacia of the Patella*. Baltimore: Williams and Wilkins, 1983.



Page printed from:

[http://www.acupuncturetoday.com/archives2001/oct/10gu.html?no\\_b=true](http://www.acupuncturetoday.com/archives2001/oct/10gu.html?no_b=true)